Journal of Cranio-Maxillo-Facial Surgery 43 (2015) 497–502

Contents lists available at ScienceDirect

Journal of Cranio-Maxillo-Facial Surgery

journal homepage: www.jcmfs.com

Relationship between intra-articular adhesions and disc position in temporomandibular joints: Magnetic resonance and arthroscopic findings and clinical results

Alejandrina Millon-Cruz*, Rafael Martín-Granizo, Alejandro Encinas, Alberto Berguer

Department of Oral and Maxillofacial Surgery, Hospital Clínico San Carlos, Calle Profesor Martin Lagos s/n, Madrid 28040, Spain

ARTICLE INFO

Article history:
Paper received 2 September 2014
Accepted 13 February 2015
Available online 24 February 2015

Keywords:
TMJ
Arthroscopy
Adhesions
Adherences
Coblation

ABSTRACT

Objective: The objective of this study was to evaluate the relationship between intra-articular adhesions (IA) and disc position on magnetic resonance imaging (MRI) and direct arthroscopic vision, and to compare the presence of IA and clinical symptoms in patients diagnosed with internal derangements (ID) of temporomandibular joint (TMJ), along with their clinical outcomes.

Methods: A total of 67 patients (134 TMJs) were included in the study. All patients were refractory to previous conservative treatment, and MRI was performed before surgery in all cases. The incidence of IA was evaluated in relation to disc displacement, type of displacement (with or without reduction), and stage of ID according to the Wilkes-Bronstein classification. Patients were divided into an adhesion and non-adhesion group. The association between the two groups with respect to preoperative clinical parameters (maximal interincisal opening, locking duration, joint pain, patient age) and postoperative parameters at 6 and 12 months was evaluated.

Results: The incidence of IA was 44% and the most common location was the anterior recess of the joint. IA were found in 58.3% of the joints with disc displacement without reduction, and in 28.9% of those with disc displacement with reduction ($p < 0.05$). In joints with well-positioned discs, adhesions were found in 15% of the cases. Patient age and locking duration were significantly higher in the adhesions group ($p < 0.05$). In relation to clinical outcome, there was no clinically relevant difference between groups at 6 and 12 months.

Conclusions: In TMJ with disc displacement without reduction, the presence of IA was significantly higher than in joints with well-positioned discs or displacement with reduction, which leads to the hypothesis that disc hypomobility is an important factor in the genesis of adhesions.

1. Introduction

Intra-articular adhesions (IA) are an important finding in patients diagnosed of internal derangements (ID) of temporomandibular joint (TMJ) treated with arthroscopy. IA or adherence is defined as bands of connective tissue that connect different intracapsular structures, but their etiology and pathogenesis is still unknown.

Several hypotheses have been proposed on the mechanism of the onset of adhesions and its relationship with articular degeneration. Kaminishi and Davis (1989) reported two theories. The first is that alterations in the lubrication system of the joint and the presence of synovitis subsequently lead to fibrin deposition and onset of adhesions. The second theory is based on the healing process of hematomas in the synovial membrane, which promotes the formation of scar tissue and adherences. Recently, Israel et al. (2006) proposed that the acute and chronic articular overload, which exceeds the adaptive mechanisms, induces articular changes and the release of inflammatory mediators and free radicals, resulting in tissue damage as synovitis, osteoarthritis, and adhesion formation.

Several classifications to rate the different types of adhesions have been proposed. First, Kaminishi and Davis (1989) classified IA as fibrous bands, fibrosynovial bands, intracapsular fibrosis, capsular fibrosis, bone-disc bands, and pseudowalls. Later, Murakami and Segami (1993) classified adhesions into 10 types

* Corresponding author. Tel.: +34 913303192.
E-mail address: amilloncruz@hotmail.com (A. Millon-Cruz).

http://dx.doi.org/10.1016/j.jcms.2015.02.010
1010-5182/

according to their severity and correlation with clinical symptoms. Yang (1998) classified adhesions into 4 groups according to their shape, size and location, as well as their involvement in disc mobility.

Nowadays, the detection of IA is performed by direct vision in arthroscopy. There are several studies of IA discovery on T2 sequences of MRI (Zhang 2009a,, Yura et al., 2011), but these studies have not yet demonstrated high accuracy for diagnosis, in contrast to disc perforations (Shen, 2014). Magnetic resonance (MR) arthrography (Yang 2005, Venetis, 2011) has a higher specificity and sensitivity for the IA diagnosis, but the high cost of this invasive technique and the need for trained personnel limit its use.

Therefore, the aims of this study were as follows: to evaluate the relationship between intra-articular adhesions (IA) and disc position on MRI and direct arthroscopic vision; and to compare the presence of IA and preoperative clinical symptoms in patients diagnosed with ID, along with their clinical outcomes at 6 and 12 months after arthroscopy surgery.

2. Material and methods

2.1. Patients

We conducted a retrospective study of 67 consecutive patients (134 TMJs) diagnosed with ID who underwent bilateral arthroscopy between January 2007 and February 2013 in our department, obtained from our database of more than 600 arthroscopies. All patients presented with unilateral or bilateral joint pain, with or without mouth opening limitation. Inclusion criteria were bilateral arthroscopy, involved bilateral TMJ disease, previous ineffective conservative treatment (soft diet, splint therapy, and physiotherapy) for at least 6 months, and 1-year follow-up. Exclusion criteria were previous TMJ open surgery, previous arthrocentesis or TMJ infiltrations, and unilateral arthroscopy.

Patients were 64 women and 3 men with a mean age of 45.3 years (range 21–68 years).

MRI of the joint was performed before surgery to evaluate the position of the articular disc. T1 and T2 sequences were done in closed and maximal mouth opening in all patients.

In all cases clinical data included joint pain using a visual analog scale (VAS), maximal interincisal opening (MIO), presence of articular clicking or locking, and duration of symptoms (in months). Follow-up evaluation was done at 6 and 12 months after surgery.

2.2. Surgery

A 1.9-mm and 30°-approach arthroscope (Dyonics HD 900, Smith & Nephew Inc., USA), including a video support, was used with 2.2-mm outer protective cannulas for diagnostic and therapeutic arthroscopy.

All arthroscopic procedures were performed by the same surgeon (R.M.G.). All subjects underwent standard bilateral arthroscopy under general anesthesia and nasothracheal intubation. After distension of the upper compartment, detection of intra-articular adhesions was performed from the posterior to the anterior aspect. The upper compartment was divided into 3 zones: posterior recess, intermediate zone, and anterior recess; and all three zones were also divided into medial and lateral parts. Adhesions were treated with lysis and lavage or were removed with a coblator electrodevice (Coblator II ENT, Arthrocare, USA) and with a biopsy forceps (Fig. 1).

After arthroscopy, all joints were classified according to the Wilkes-Bronstein classification system from stage II to V. Furthermore, patients were divided into two groups: an adhesion group and non-adhesion group.

2.3. Evaluation

We evaluated the incidence, features, and location of adhesions in our sample and their distribution according to the stage of joint degeneration (II–V). The incidence of adhesions and their relationship to the presence and type of disc displacement was also studied.

The difference between the adhesion and non-adhesion groups was analyzed with respect to preoperative clinical data and clinical outcome at 6 and 12 months after surgery.

2.4. Statistical analysis

All statistical analysis was done using SPSS 15.0.1 for Windows (SPSS Inc. USA). All variables were divided into continuous and categorical variables. A Student's t-test and t-test for paired samples were used for continuous variables. A χ^2 test was used for categorical variables. A p value of <0.05 was considered statistically significant.

3. Results

IA were observed in 59 (44%) of the 134 treated joints. The most common location was the anterior recess, with 44% of adhesions, mainly in the medial part, followed by the intermediate zone (39% of adhesions) and, finally, the posterior recess (19% of adhesion) (Fig. 2).

MRI of the TMJ before surgery revealed 14% of the joints with a well-positioned disc, displacement with disc reduction in 28%, and disc displacement without reduction in 54% of joints. In the rest, 4% of the joints, a stuck disc was observed.

3.1. Adhesions and disc position

IA were found in 58.3% of joints with disc displacement without reduction, in contrast to the joints with disc displacement with reduction, of which 28.9% showed adhesions and 15.8% of the joints showed well-positioned discs. These differences were statistically significant in χ^2 analysis ($p < 0.05$) (Table 1).

3.2. Adhesions and ID stages

A higher incidence of adhesions was found in joints with advanced stages in the Wilkes-Bronstein classification. Adhesions were present in 26.7% of joints (15/56) in stage II, in contrast to 65% of joints (13/20) with adhesions in stage IV and 80% of joints (8/10) in stage V. These differences were statistically significant in χ^2 analysis ($p < 0.05$) (Table 2).

3.3. Adhesions and clinical symptoms

In the comparative analysis between the adhesion group and non-adhesion group (45 and 21 patients, respectively), the only statistically significant differences were the duration of mouth opening limitation and the age of patients ($p < 0.05$), which were higher in the adhesion group (Table 3).

In the follow-up period, both groups showed a statistically significant improvement in pain after surgery ($p < 0.05$). The adhesion group showed a mean improvement of 49.73 points in VAS 12 months after surgery, whereas the non-adhesion group showed a mean improvement of 47.91 points. No significant differences between groups were observed (Fig. 3).

Each group experienced significantly increased oral opening at 6 and 12 months after surgery ($p < 0.05$). The non-adhesion group presented with a significantly greater MIO at 12 months after

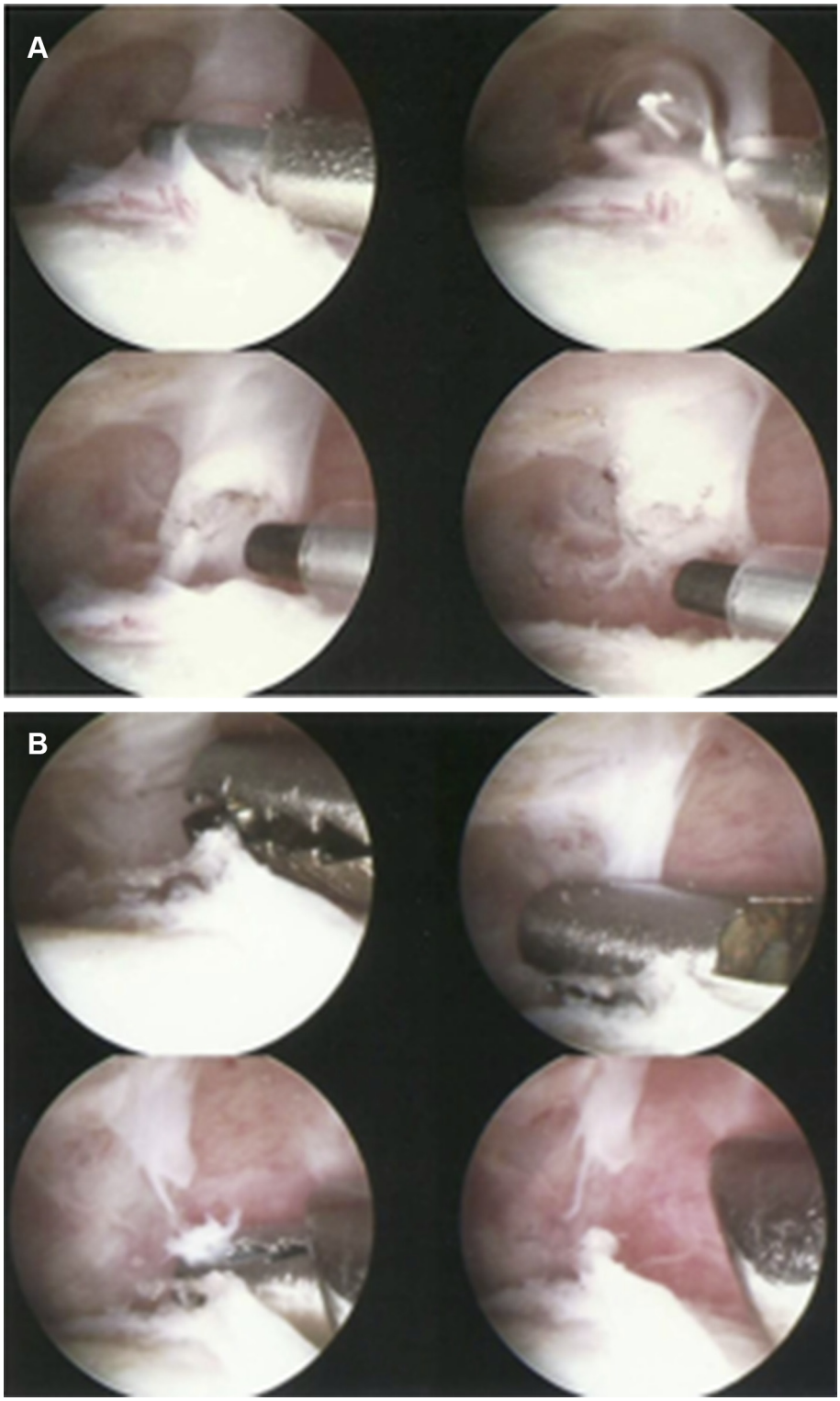

Fig. 1. Arthroscopic treatment of adhesion. (A) Treatment with coblator electrodevice in the right-side temporomandibular joint (TMJ). (B) Use of biopsy forceps to treat an adhesion in the antero-medial part of the right TMJ.

surgery (mean 41.12 mm) compared to the adhesion group, which had a mean MIO of 38.45 mm ($p < 0.05$) (Fig. 4).

Regarding joint clicks and locking, no significant differences between groups were observed. Articular locking decreased significantly in both groups at 6 and 12 months.

4. Discussion

IA are a common arthroscopic finding in patients with ID, although the incidence varies according to different studies, ranging from 28.7% to 100% of the joints treated. This wide range of

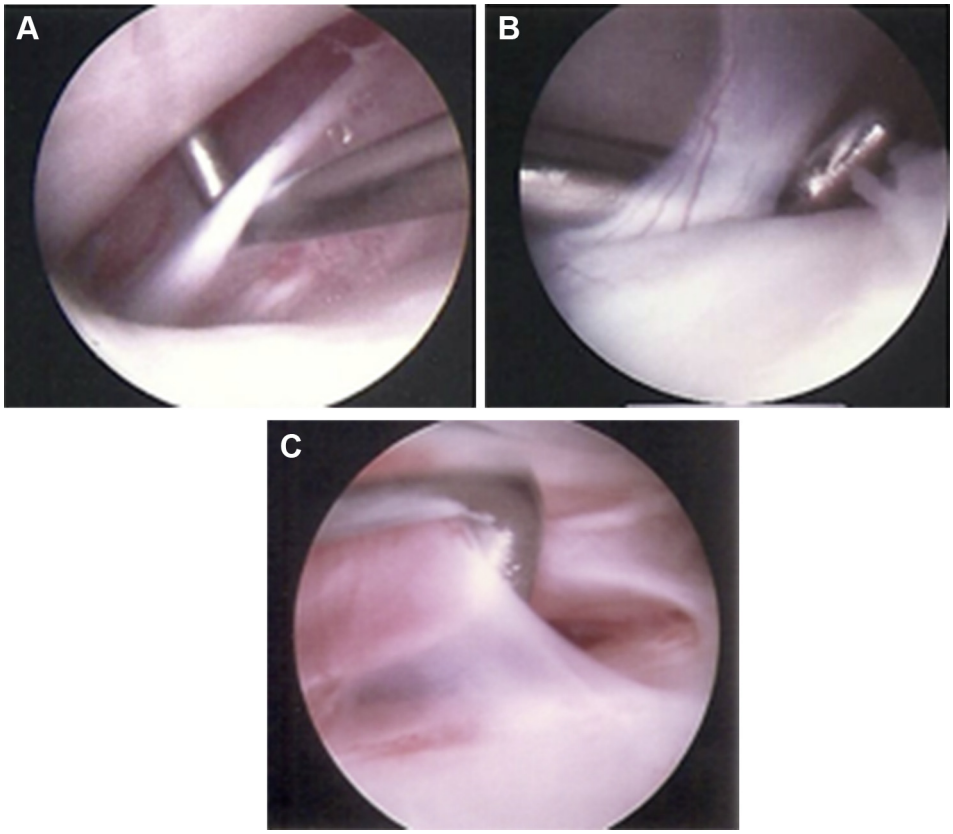

Fig. 2. Intra-articular adhesions. (A) Fibrous adhesion in the anterior compartment of joint. (B) Fibrosynovial adhesion. (C) Pseudowall adhesion in medial zone.

incidence observed could be explained by the inclusion of patients at different stages in the Wilkes-Bronstein classification. Previous studies (Israel et al., 2006; Zhang et al., 2009b) have reported a direct relationship between the degree of joint degeneration and the appearance of adhesions. Murakami and Segami (1993) and Leibur et al. (2010) reported a high incidence of adhesions (91% and 100%, respectively); however, in the Segami and Murakami study, 44.12% of the sample was in advanced stages of ID (IV and V), and in the Leibur et al. study, all of the patients presented in advanced stages, in contrast with the study by Zhang et al., 2009b, in which the majority of cases were in stages II and III (65.9%) with an IA incidence of 28.7%. In our study, we found a similar percentage of cases in early stages of ID, but the incidence of IA was higher than in the Zhang et al. study. It was also observed that the number of adhesions in a joint increased in advanced stages, with the finding, in these cases, of more than 2 and 3 adhesions in the same joint.

Regarding the location of adhesions inside the TMJ, our result is similar to those of other studies (Zhang et al., 2009b; Machoň et al., 2012), in which the most common location was the anterior recess. However, Zhang divided the joint into 3 compartments: anterior (I), intermediate (II), and posterior (III), and reported that 82.13% of adhesions were in the anterior compartment, mainly in the intermediate and lateral areas of the anterior compartment (20.8% and 36.43%, respectively). These results differ slightly from our own, in which the most common location is the medial part of the anterior recess, followed by the intermediate area. Nevertheless, it should be noted that, when using arthroscopy to diagnose adhesions, there is a dead angle in the camera to the lateral area of the joint (puncture zone), and small or thin adhesions could remain undiagnosed. Only MR arthrography showed high specificity and sensitivity to detect adhesions and disc perforations (Venetis et al., 2011), but the results were similar to those for arthroscopy.

In our study, we found a significant relationship between the presence of adhesions and disc displacement without reduction when compared to joints with disc displacement with reduction or joints with well-positioned discs. The reason could be that disc hypomobility may be a factor in the genesis of adhesions. The same conclusions were drawn in the study by Murakami et al. (1992), in

Table 1
Relationship between adhesions and disc position.

Disc position	Adhesions (n = 56)	Non-adhesions (n = 73)	Total
Normal	3 (15.8%)*	16 (84.2%)	19 (100%)
DDwR	11 (28.9%)*	27 (71.1 %)	38 (100%)
DDwoR	42 (58.3%)*	30 (41.7%)	72 (100%)
Total	56 (43.41%)	73 (56.58%)	129 (100%)

Number of patients and percentage in each group are reported. Joints with stuck disc were excluded.
*Statistically significant results ($p < 0.05$).

Table 2
Relationship between adhesions and internal derangement (ID) stages.

ID stage	Number of adhesions				Total adhesions	Total TMJ
	No	1	2	3		
II	41 (73.2%)	12 (21.4%)	3 (5.3%)	0	15 (26.7%)*	56 (41.8%)
III	25 (52%)	18 (37.5%)	5 (10.4%)	0	23 (47.9%)*	48 (35.82%)
IV	7 (35%)	11 (55%)	2 (10%)	0	13 (65%)*	20 (14.9%)
V	2 (20%)	6 (60%)	1 (10%)	1 (10%)	8 (80%)*	10 (7.46%)
Total	75 (56%)	47 (35.1%)	11 (8.2%)	1 (0.7%)	59 (44%)	134 (100%)

TMJ, temporomandibular joints.
Number of patients and percentage in each group are reported.
*Statistically significant results ($p < 0.05$).

Table 3
Intra-articular adhesions and preoperative clinical symptoms.

	Adhesion group n = 45	Non-adhesion group n = 21	*p* Value
Pain (VAS)	69.76 ± 21.15	65.83 ± 24.48	0.382
Paining duration (>12 mo)	70.5%	66.7%	0.798
MIO pre-surgery (mm)	31.67 ± 6.73	34.38 ± 7.11	0.143
Opening limitation duration (>12 mo)	39.5%	9.5%	0.014*
Clicking	65.8%	63.2%	0.844
Clicking duration (>12 mo)	45.9%	47.4%	0.838
Age (y)	42.96 ± 13.61	36.57 ± 10.21	0.039*
Articular locking	26	15	0.528

MIO, maximal interincisal opening; VAS, visual analog scale.
Categorical variables are presented as number of patients and percentage in each group. Continuous variables are presented in mean ± standard deviation.
*Statistically significant results ($p < 0.05$).

which IA was associated with chronic disc displacement. Also, Zhang et al., 2009b suggested that the disc with anterior displacement compresses the synovium in the anterior recess of the joint, leading to inflammatory changes that produce an inflammatory exudate that concentrates in this declining area and promotes the onset of adhesions. That also explains why adhesions are more common in this area. On the other hand, some authors hypothesize that disc displacement is the final result of degenerative changes in joint tissues, as in synovitis, osteoarthritis, and adhesions, rather than being the cause (Stegenga et al., 2001).

With regard to IA and clinical symptoms before surgery, comparing both groups, we obtained results similar to those of other studies (Machoň et al., 2012; Zhang et al., 2009a,b; Murakami et al., 1992). The only significant difference between groups was in the age and the duration of mouth opening limitation, which is consistent with previous studies. However, although the mean difference in preoperative mouth opening was greater in the non-adhesion group than in the adhesion group, these values were not significant, which differs from previous studies (Zhang et al., 2009b). The reason could be that the sample was insufficient. In relation to lateral movements, Murakami et al. reported a significant decrease of lateral movements in the adhesion group, but in our study lateral movements were not recorded. As in other studies, we found no relationship between adhesions and joint pain or pain duration.

At follow-up in our study, both groups showed a significant improvement at 6 and 12 months after surgery in oral opening. When comparing both groups, significant differences were observed in oral opening at 12 months, being higher in the non-adhesion group; however, this could be because this group

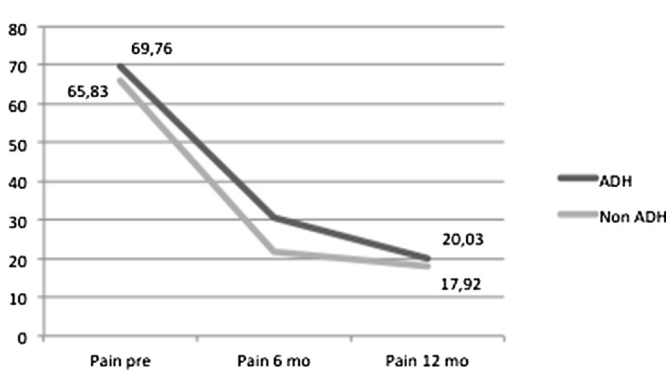

Fig. 3. Pain on the visual analog scale (VAS) before and 1 year after surgery. No statistically significant differences in improvement of pain between groups were observed. ADH, adhesion group; Non ADH, non-adhesion group.

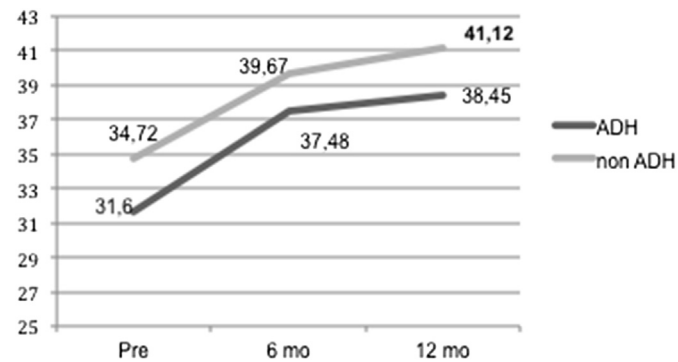

Fig. 4. Interincisal opening before and 6 and 12 months after surgery. Significant differences at 12 months in maximal interincisal opening (MIO) between non-adhesion and adhesion groups ($p < 0.05$). ADH, adhesion group; Non ADH, non-adhesion group.

presented with a higher preoperative oral opening and the adhesion group presented more advanced stages of joint degeneration, and therefore a worse prognosis despite treatment.

In relation to pain and articular locking after treatment, both variables showed significant improvement when compared to the previous values, and there was no difference between groups. These results are similar to those of other studies (Zhang et al., 2011; Machoň et al., 2012; Leibur et al., 2010).

5. Conclusions

Intra-articular adhesions are a common arthroscopic finding and are located most frequently in the anterior joint recess of the TMJ. In joints with disc displacement without reduction, the presence of IA was significantly higher than in those with displacement with reduction; but when TMJ function before surgery in the adhesion and non-adhesion groups was compared, no difference was found between groups. Thus it is not possible to conclude, based on this study, that disc hypomobility could play an important role in the genesis of adhesions. In relation to clinical symptoms, we observed a higher incidence of adhesions in patients with longer limited mouth opening and in older patients. After surgery, we found no significant differences in patients with or without adhesions and observed significant improvement in both groups. We conclude that it is important to diagnose and treat patients as soon as possible to benefit from surgery and to obtain better results.

Conflict of interest

The authors report no conflicts of interest.

References

Israel HA, Langevin CJ, Singer MD, Behrman DA: The relationship between temporomandibular joint synovitis and adhesions: pathogenic mechanisms and clinical implications for surgical management. J Oral Maxillofac Surg 64: 1066–1074, 2006
Kaminishi RM, Davis CL: Temporomandibular joint arthroscopic observation of superior space adhesions. Oral Maxillofac Surg Clin North Am 1: 103, 1989
Leibur E, Jagur O, Müürsepp P, Veede L: Long-term evaluation of arthroscopic surgery with lysis and lavage of temporomandibular joint disorders. J Craniomaxillofac Surg 38: 615–620, 2010
Machoň V, Sedý J, Klíma K, Hirjak D, Foltán R: Arthroscopic lysis and lavage in patients with temporomandibular anterior disc displacement without reduction. Int J Oral Maxillofac Surg 41: 109–113, 2012
Murakami K, Segami N, Moriya Y, Iizuka T: Correlation between pain and dysfunction and intra-articular adhesions in patients with internal derangement of the temporomandibular joint. J Oral Maxillofac Surg 50: 705–708, 1992
Murakami K, Segami N: Intraarticular adhesions of the temporomandibular joint. In: Clark GT, Sanders Bertolami CN (eds), Advances in diagnostic and surgical

arthroscopy of the temporomandibular joint, 15. Philadelphia: WB Saunders, 1993

Shen P, Hou L, Zhang S, Yang C, Cai X: Magnetic resonance imaging applied to the diagnosis of perforation of the temporomandibular joint. J Craniomaxillofac Surg 42: 874–878, 2014

Stegenga B: Osteoarthritis of the temporomandibular joint organ and its relationship to disc displacement. J Orofac Pain 15: 193, 2001

Venetis G, Pilavaki M, Triantafyllidou K, Papachristodoulou A, Lazaridis N, Palladas P: The value of magnetic resonance arthrography of the temporomandibular joint in imaging disc adhesions and perforations. Dentomaxillofac Radiol 40: 84–90, 2011

Yang C: The clinical application of TMJ arthroscopy. In: QIU WL (ed.), Theory and practice of oral and maxillofacial surgery. Peking: People's Medical Publishing House (PMPH), 1389, 1998

Yang C, Zhang SY, Wang XD, Fan XD: Magnetic resonance arthrography applied to the diagnosis of intraarticular adhesions of the temporomandibular joint. Int Oral Maxillofac Surg 34(7): 733–738. http://dx.doi.org/10.1016/j.ijom.2005.02.011, 2005

Yura S, Nobata K, Shima T: Diagnostic accuracy on fat-saturated T2 weighted MRI for diagnosis of intra-articular adhesions of the temporomandibular joint. Dentomaxillofac Radiol 40: 84–90, 2011

Zhang SY, Huang D, Liu X, Yang C, Undt G, Haddad SM, et al: Arthroscopic treatment for intra-articular adhesions of the temporomandibular joint. J Oral Maxillofac Surg 69: 2120–2127, 2011

Zhang S, Yang C, Chen M, Fan X, Yun B, Peng Y: Magnetic resonance imaging in the diagnosis of intra-articular adhesions of the temporomandibular joint. Br J Oral Maxillofac Surg 47: 389–392, 2009a

Zhang SY, Liu X, Yang C, Cai X, Chen M, Haddad SM, et al: Intra-articular adhesions of the temporomandibular joint: relation between arthroscopic findings and clinical symptoms. BMC Musculoskelet Disord 10: 70, 2009b